

## Review Article

# Expert Consensus Recommendations for the Performance of Peripheral Nerve Blocks for Headaches – A Narrative Review

Andrew Blumenfeld, MD; Avi Ashkenazi, MD; Uri Napchan, MD; Steven D. Bender, DDS;  
Brad C. Klein, MD; Randall Berliner, MD; Jessica Ailani, MD; Jack Schim, MD;  
Deborah I. Friedman, MD, MPH; Larry Charleston IV, MD; William B. Young, MD;  
Carrie E. Robertson, MD; David W. Dodick, MD; Stephen D. Silberstein, MD; Matthew S. Robbins, MD

**From The Headache Center of Southern California – Neurology, Encinitas, CA, USA (A. Blumenfeld and J. Schim); Doylestown Hospital, Doylestown, PA, USA (A. Ashkenazi); Headache Clinic at Middletown Medical, Middletown, NY, USA (U. Napchan); North Texas Center for Head, Face & TMJ Pain, Texas A&M University, Baylor College of Dentistry, Plano, TX, USA (S.D. Bender); Abington Headache Center – Neurology, Warminster, PA, USA (B.C. Klein); Albert Einstein College of Medicine/Montefiore Medical Center, Bronx, NY, USA (R. Berliner and M.S. Robbins); Department of Neurology, Georgetown University Hospital, Washington, DC, USA (J. Ailani); Departments of Neurology & Neurotherapeutics and Ophthalmology, University of Texas Southwestern Medical Center, Dallas, TX, USA (D.I. Friedman); Spectrum Health Medical Group Comprehensive Headache Care Center – Neurology, Grand Rapids, MI, USA (L. Charleston IV); Neurology, Michigan State University College of Human Medicine, Grand Rapids, MI, USA (L. Charleston IV); Thomas Jefferson University – Neurology, Philadelphia, PA, USA (W.B. Young and S.D. Silberstein); Neurology Department, Mayo Clinic, Rochester, MN, USA (C.E. Robertson); Neurology, Mayo Clinic, Scottsdale, AZ, USA (D.W. Dodick).**

**Address all correspondence to M.S. Robbins, Saul R. Korey Department of Neurology, Montefiore Headache Center, Albert Einstein College of Medicine, Bronx, NY 10461, USA.**

**Accepted for publication May 2, 2012.**

*Conflict of Interest:* Dr. Blumenfeld reports no conflict of interest in relation to nerve blocks. He does have consulting agreements, research grants, and/or speaking contracts with Allergan, Merz, Ipsen, Forrest, Pfizer, Posen, Zogenix, MAP Pharm, Impax. Dr. Ashkenazi – reports no conflicts. Dr. Napchan – received honoraria from GlaxoSmithKline and Zogenix. Dr. Bender – member of the advisory board of Nautilus Neurosciences and a member of the speakers bureau of IMPAX Pharmaceuticals. Dr. Klein – reports no conflict of interest. Dr. Berliner – received honoraria from Allergan, Nautilus, and Zogenix. Dr. Ailani – reports no conflicts. Dr. Schim – member of the advisory boards of Allergan, Zogenix, and MAP – honoraria: Allergan, Zogenix, Pfizer. Dr. Friedman – reports no conflicts. Dr. Charleston – reports no conflicts. Dr. Young – received funding for travel and speaker honoraria from Allergan, GlaxoSmithKline, Iroco, Merck, and Zogenix; serves as a consultant for Merz Pharmaceuticals; received research support from AGA Medical, Advanced Bionics, Advanced Neuromodulation Systems, Allergan, Capnia, Chorus (Lilly), Eli Lilly, Endo Pharmaceuticals, GlaxoSmithKline, MAP Pharmaceuticals, Medtronic, Minster, National Institute of Neurological Disorders and Stroke/National Institutes of Health, NuPathe, and Valeant; and receives royalties from *Migraine and Other Headaches (2004)* published by Demos Medical. Dr. Robertson – reports no conflicts. Dr. Dodick – research grants from Advanced Neurostimulation Systems, Boston Scientific, Mayo Clinic, Medtronic, NINDS/NIH, St. Jude Medical Inc. Honoraria: Alexza, Allergan, Kowa, ATI, Boston Scientific, Bristol Myers Squibb, Coherex, Eli Lilly & Company, Endo, HS Lunbeck, MAP Pharmaceuticals, Merck Serono, Medtronic, Inc., Minster, Nautilus, Neuralie, Neuraxon, NuPathe, Inc., Novartis, Pfizer, SmithKlineBeecham. Speakers bureau for: Annenberg Center, CogniMed, Intramed, SAGE Publishing, Lippincott Williams and Wilkins, Oxford University Press, Cambridge University Press, Miller Medical. Dr. Silberstein – honoraria: Amgen, AGA, Allergan, Boston Scientific, Capnia, Coherex, Colucid, GlaxoSmithKline, Lilly, MAP, Medtronic, Merck, NINDS, Nupathe, Novartis, Pfizer, St. Jude Medical, Valeant. He is part of the speakers bureau for Endo Pharmaceuticals, GlaxoSmithKline, Merck. Research grants have been received from: AGA, Allergan, Amgen, Boston Scientific, Capnia, Coherex, Endo Pharmaceuticals, GlaxoSmithKline, Lilly, Map, Medtronic, Merck, Minister, Neuralie, Novartis, NINDS, NuPathe, Opt-Nose, Pfizer, St. Jude Medical, Valeant Pharmaceuticals. Dr. Robbins – reports no conflicts.

### Disclaimer

This publication is neither an official position paper nor an official guideline from the American Headache Society.

**Objective.**—To describe a standardized methodology for the performance of peripheral nerve blocks (PNBs) in the treatment of headache disorders.

**Background.**—PNBs have long been employed in the management of headache disorders, but a wide variety of techniques are utilized in literature reports and clinical practice.

**Methods.**—The American Headache Society Special Interest Section for PNBs and other Interventional Procedures convened meetings during 2010-2011 featuring formal discussions and agreements about the procedural details for occipital and trigeminal PNBs. A subcommittee then generated a narrative review detailing the methodology.

**Results.**—PNB indications may include select primary headache disorders, secondary headache disorders, and cranial neuralgias. Special procedural considerations may be necessary in certain patient populations, including pregnancy, the elderly, anesthetic allergy, prior vasovagal attacks, an open skull defect, antiplatelet/anticoagulant use, and cosmetic concerns. PNBs described include greater occipital, lesser occipital, supratrochlear, supraorbital, and auriculotemporal injections. Technical success of the PNB should result in cutaneous anesthesia. Targeted clinical outcomes depend on the indication, and include relief of an acute headache attack, terminating a headache cycle, and transitioning out of a medication-overuse pattern. Reinjection frequency is variable, depending on the indications and agents used, and the addition of corticosteroids may be most appropriate when treating cluster headache.

**Conclusions.**—These recommendations from the American Headache Society Special Interest Section for PNBs and other Interventional Procedures members for PNB methodology in headache disorder treatment are derived from the available literature and expert consensus. With the exception of cluster headache, there is a paucity of evidence, and further research may result in the revision of these recommendations to improve the outcome and safety of these interventions.

**Key words:** peripheral nerve block, lidocaine, intervention, peripheral nerve block, intervention, greater occipital, lesser occipital, supratrochlear, supraorbital, auriculotemporal, headache, migraine, cluster headache, lidocaine, bupivacaine, corticosteroid

(*Headache* 2013;53:437-446)

---

Peripheral nerve blocks (PNBs) have been used for the acute and preventive treatment of a variety of primary headache disorders for decades.<sup>1-3</sup> These procedures provide prompt pain relief for many patients with various headache types. Moreover, their analgesic effect typically lasts beyond the duration of anesthesia caused by the nerve blockade, providing some patients with pain relief for several weeks or even months.<sup>4</sup> This prolonged analgesia after peripheral nerve blockade may be due to an effect on central pain modulation.<sup>5</sup> The most widely used target for PNBs is the greater occipital nerve (GON). Other commonly targeted nerves are the lesser occipital nerve (LON) and several branches of the trigeminal nerve, including the supratrochlear (STN), supraorbital (SON), and auriculotemporal nerves (ATN). PNBs are generally safe and well-tolerated procedures that may be performed in the outpatient setting. A sound knowledge of the anatomy of the different nerves is critical for obtaining good results and for avoiding adverse effects (AEs) such as bleeding or inadvertent systemic injection of the drugs used for nerve blockade.

Despite the common use of PNBs by clinicians involved in the care of patients with headache, there

has been no standardized approach for the performance of these procedures. A recent survey conducted by the American Headache Society Special Interest Section for PNBs and other Interventional Procedures (AHS-IPS) showed that 69% of responding practitioners used PNBs; however, patterns of use, drug dosages, volumes of injections, and injection schedules varied greatly.<sup>2</sup>

To address this issue, members of the AHS-IPS convened, aiming to reach a consensus on the recommended techniques for the performance of PNBs for headaches. In this report, we summarize the results of this effort.

## METHODS

This endeavor was initiated by a systematic literature review<sup>2</sup> and a survey of the AHS membership<sup>3</sup> by the AHS-IPS that established the need for standardized PNB methodology. Section meetings were convened during the 2010 AHS Scottsdale Headache Symposium and the 2011 AHS annual scientific meeting in Washington, DC, with a cross-section of the AHS membership who are active with PNBs, featuring formal discussion about each methodological

**Table 1.—Potential Indications for Peripheral Nerve Blocks in the Treatment of Headache Disorders**

| Headache Disorder             | Nerve(s) Blocked | Evidence  |
|-------------------------------|------------------|---|
| Primary headache disorders    |                  |   |
| Migraine                      | GON, STN, SON    | Retrospective <sup>23-25</sup><br>Prospective, noncontrolled <sup>12,26</sup>   |
| Cluster headache              | GON              | Case series <sup>4,13</sup><br>Open label <sup>14</sup><br>Retrospective <sup>15</sup><br>Double blind, placebo controlled <sup>7,8</sup>   |
| Chronic daily headache        | GON              | Case series <sup>4</sup><br>Open label <sup>27</sup><br>Prospective, noncontrolled <sup>28</sup><br>Prospective, randomized controlled <sup>20</sup>  |
| Hemicrania continua           | GON, SON         | Case series <sup>4,18</sup>   |
| New daily persistent headache | GON              | Case series <sup>4,29</sup>   |
| Secondary headache disorders  |                  |   |
| Cervicogenic headache         | GON, LON, SON    | Case series <sup>30,31</sup><br>Retrospective <sup>25</sup><br>Prospective, noncontrolled <sup>32</sup><br>Prospective, comparative <sup>33</sup><br>Double blind, placebo controlled <sup>34</sup> |
| Post-traumatic headache       | GON              | Retrospective <sup>35</sup>   |
| Post-dural puncture headache  | GON, LON         | Prospective, comparative <sup>36</sup>  |
| Cranial neuralgias            |                  |   |
| Supraorbital neuralgia        | SON              | Case series <sup>37-39</sup>  |
| Auriculotemporal neuralgia    | ATN              | Case series <sup>40</sup>   |

ATN = auriculotemporal nerve; GON = greater occipital nerve; LON = lesser occipital nerve; SON = supraorbital nerve; STN = supratrochlear nerve.

point, and majority rule for consensus. No formal vote was required as an agreement was reached on each point by the AHS-IPS. The manuscript was then drafted and revised by a subcommittee of the AHS-IPS (authors of this manuscript) from July to November 2011. After consultation with the AHS Guidelines Committee and the Board of Directors throughout 2012, the manuscript was determined to be best framed as a narrative review by the AHS-IPS; further edits were implemented, followed by final manuscript submission with full approval from all authors.

## RESULTS

**PNB Indications and Contraindications.**—*Indications.*—The potential indications for PNBs in headache disorders have recently been addressed in a systematic review.<sup>2</sup> In Table 1, we list the potential indications for PNBs including disorders that were not previously addressed, eg, auriculotemporal and supraorbital neuralgia.

*Contraindications.*—Current literature does not support absolute or relative contraindications to the performance of PNBs. In Table 2, we address some practical and theoretical concerns for the performance of PNBs in various patient populations.

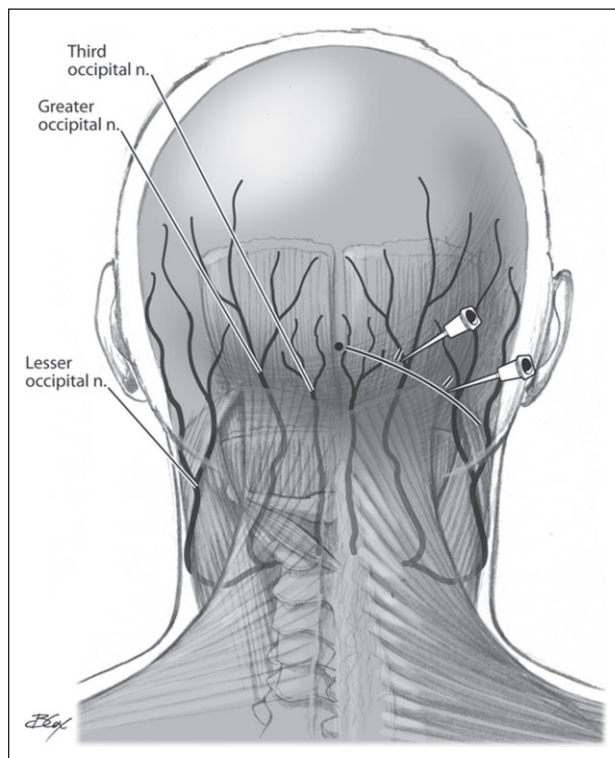
In order to minimize AEs, the doses of local anesthetics per treatment session should be limited to <300 mg of lidocaine or <175 mg of bupivacaine.<sup>6</sup>

**PNB Methods.**—*GON Block.*—*Location of injection:* the GON arises from the posterior division of the second cervical nerve as the medial branch. It ascends obliquely between the obliquus capitis inferior and the semispinalis capitis, and pierces the semispinalis capitis and the trapezius near their attachments to the occipital bone. The GON provides sensation to the posterior scalp, medially. The GON may be localized for injection by imagining a line from the occipital protuberance to the mastoid process and moving 1/3 of the way laterally (Fig. 1). Notably, the occipital artery courses next to the GON (often, although not invariably,

**Table 2.—Potential Precautions and Contraindications for Peripheral Nerve Blocks in the Treatment of Headache Disorders**

| Patient Population   | Concern  | Action   |
|--|--|--|
| Local anesthesia allergy   | Allergic reaction, including anaphylaxis               | PNB with local anesthetic contraindicated<br>Use corticosteroids only <sup>19</sup>  |
| Elderly  | Hypotension<br>Hypertension                            | Reduce concentration of anesthetic (avoid lidocaine 5%) <sup>41</sup><br>Limit number of nerves to be blocked in a single session<br>Restrict PNB to unilateral GON injection if possible  |
| Pregnancy  | Teratogenicity   | Use lidocaine (FDA Category B) over bupivacaine (FDA Category C)<br>Avoid betamethasone and dexamethasone (accelerate fetal lung development)<br>Caution is warranted in the use of any corticosteroids in the pregnant population |
| Prior vasovagal attacks<br>Prior syncopal attacks                                  | Vasovagal reaction<br>Presyncope or syncope            | Perform PNB in supine position, where feasible<br>Use bupivacaine instead of lidocaine<br>Reduce concentration of anesthetic agent<br>Allow for extra time in the supine position after the procedure as a precaution              |
| Open skull defect<br>Craniotomy<br>Anticoagulation therapy<br>Antiplatelet therapy | Intracranial diffusion of anesthetic agent<br>Hematoma | PNB contraindicated <sup>42,43</sup><br>Extra attention to palpate for (and avoid) neighboring arteries (occipital, temporal)<br>Compress at each PNB site for 5-10 minutes  |
| Cosmetic concerns  | Alopecia<br>Cutaneous atrophy                          | Avoid corticosteroids<br>If methylprednisolone must be used, dose <80 mg in GON region <sup>10</sup>   |

FDA = Food and Drug Administration; GON = greater occipital nerve; PNB = peripheral nerve block.



**Fig 1.—Greater and lesser occipital nerve blocks.**

lateral to the nerve), therefore care needs to be taken to avoid intra-arterial injection. Palpating for the point of maximal tenderness may improve accuracy.<sup>4</sup> Injections may be performed unilaterally or bilaterally.

*Technique of injection:* use a 3 mL or a 5 mL syringe with a 25-, 27-, or 30-gauge, 0.5- or 1-inch needle. Insert the needle to a depth of 3-4 mm, then slightly withdraw the needle, pull the plunger to verify that the needle is not intravascular, then inject the solution in a single injection or use a fan-like distribution.

*Drugs to use:* lidocaine 1%-2% (10-20 mg/mL) and/or bupivacaine 0.25%-0.5% (2.5-5 mg/mL). If a combination of the 2 drugs is used, the recommended volume ratio (lidocaine/bupivacaine) is 1:1-1:3.

*Volume of injection:* 1.5-3 mL per nerve.

Evidence to support the routine addition of corticosteroids to local anesthetics when performing GON block for headache is strongest for cluster headache (CH) patients.<sup>2,7,8</sup> However, corticosteroids may be added to local anesthetics for other headache diagnoses as well, if patients do not respond adequately to local anesthetics alone.

Assess for (and aim to achieve) numbness in the area of the GON dermatome (this should occur within 5 minutes after lidocaine injection, and within 10-15 minutes after bupivacaine injection). This may be accomplished by applying a pin to the sensory distribution served by the GON, distant from the injection site, and assessing for sharpness vs bluntness. Having the patient compare sharpness at the GON skin area vs an area not served by the GON may also be useful.

For patients who require repeated injections, the recommended frequency of treatments is once every 2-4 weeks, depending on response of the individual patient. If steroids are administered on a repeated basis, injections should be performed less frequently, usually at intervals no shorter than 3 months. However, this interval may be shorter for patients with CH.<sup>7</sup>

**LON Block.**—*Location of injection:* the LON arises from the second cervical nerve, and sometimes from the third as part of the cervical plexus. It ascends along the posterior border of the sternocleidomastoid muscle, supplying the skin lateral to the GON and posterior to the greater auricular nerve. It may be localized for injection by drawing the same line used to localize the GON, but by moving 2/3 of the way laterally from the occipital protuberance (Fig. 1).

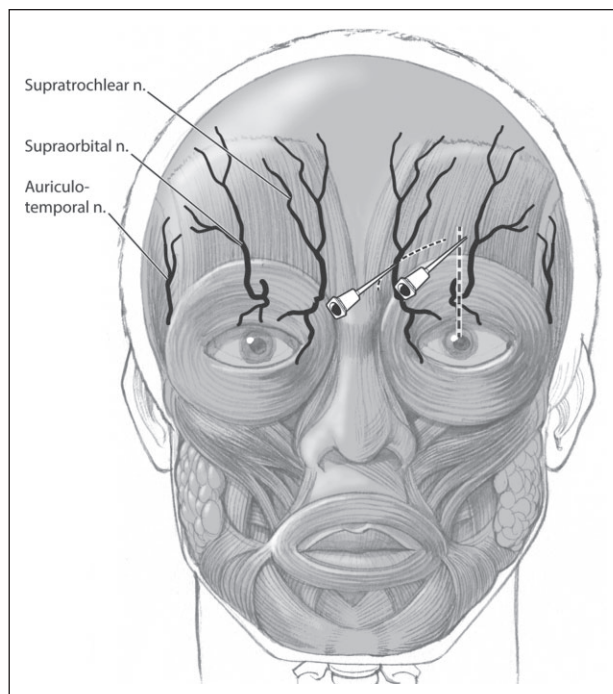
*Volume of injection:* 1-2 mL per nerve.

The drugs and technique of injection are similar to those used for GON block.

**Trigeminal Nerve Blocks.**—**STN Block.**—The STN is a terminal branch of the frontal nerve, the largest branch of the ophthalmic division of the trigeminal nerve (Fig. 2). It runs medially above the trochlea in the roof of the orbit, ascends onto the forehead through the frontal notch, and arcs up on the forehead close to the bone with the supratrochlear artery to supply the skin and conjunctiva covering the upper eyelid, and the skin over the forehead. The STN is located medial to the SON.

*Location of injection:* at the superomedial aspect of the orbit (Fig. 2).

*Technique of injection:* use a 1 mL syringe with a 30-gauge, 0.5-inch needle. Insert the needle at the medial aspect of the corrugator muscle, a fingerbreath lateral to the procerus, to a depth of 3-4 mm. After



**Fig 2.—Supratrochlear and supraorbital nerve blocks.**

negative aspiration, inject the solution. An alternative technique is to identify the supraorbital ridge by palpation. The needle is then inserted lateral to the ridge and is advanced medially into the subcutaneous tissue. After negative aspiration, the solution is injected. Pressure should be applied to avoid periorbital hematoma.

*Drugs to use:* lidocaine 1%-2% (10-20 mg/mL) and/or bupivacaine 0.25%-0.5% (2.5-5 mg/mL). If a combination of the 2 drugs is used, the recommended volume ratio (lidocaine/bupivacaine) is 1:1-1:3. We do not recommend the use of corticosteroids in this area, or in other trigeminal territories.

*Volume of injection:* 0.2-1.0 mL per nerve.

For patients who require repeated injections, the recommended frequency of treatments is once every 2-4 weeks, depending on the response of the individual patient.

**SON Block.**—The SON is the larger of the 2 terminal branches of the frontal nerve. It courses through the supraorbital notch or foramen and supplies palpebral filaments to the upper eyelid and conjunctiva. It then ascends on the forehead with the supraorbital artery and divides into medial and



lateral branches, which supply the skin of the scalp almost as far back as the lambdoid suture. The medial branch pierces the occipitofrontalis muscle to reach the skin, while the lateral branch penetrates the epicranial aponeurosis over the forehead and scalp. Postganglionic sympathetic fibers, which innervate the sweat glands of the supraorbital area, are thought to travel in the SON. The supraorbital notch or foramen lies on the superior aspect of an imaginary line coursing caudally and intersecting the pupil, the infraorbital foramen, and the mental foramen.

*Location of injection:* above the supraorbital notch.

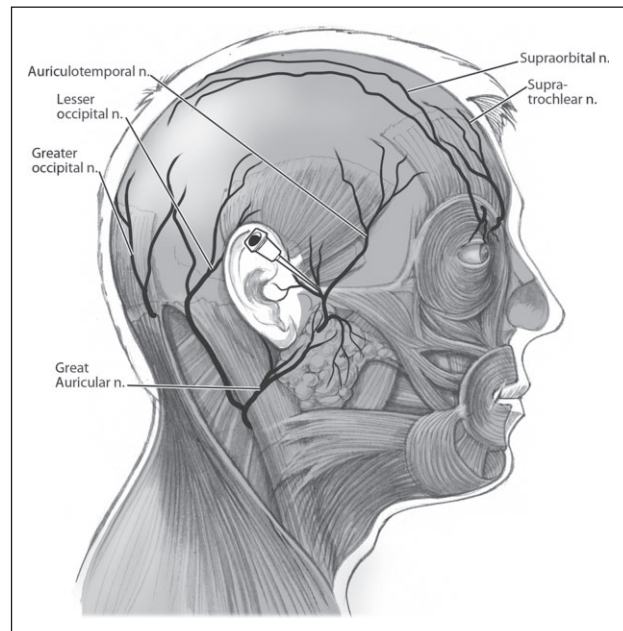
*Technique of injection:* use a 1 mL syringe with a 30-gauge, 0.5-inch needle. Insert the needle at the corrugator muscle, at the mid-pupillary line (Fig. 2). After negative aspiration, the solution may be injected at a depth of 3-4 mm. An alternative technique is to identify the supraorbital notch by palpation, at the superior margin of the orbit, mid-pupillary line. The needle is then advanced medially and inserted at a slight angle to avoid entering the foramen. The solution then may be injected at a depth of 3-4 mm, after negative aspiration. Pressure should be applied to avoid periorbital hematoma. Alternatively, after blocking the STN, redirect the needle laterally and inject.

Drugs used and volume of injections are the same as for the STN block.

**ATN Block.**—The ATN surfaces onto the face from behind the temporomandibular joint (TMJ) within the superior surface of the parotid gland. It ascends close to the superficial temporal artery, passes over the posterior portion of the zygoma, and divides into superficial temporal branches. The cutaneous branches of the ATN supply the tragus and part of the adjacent auricle of the ear and the posterior part of the temple. The ATN also provides sensory innervation to the majority of the TMJ.

*Location of injection:* just anterior to the tragus (Fig. 3).

*Technique of injection:* palpate for the temporal artery along its course anterior to the tragus and inject 2 mm anterior to it at a depth of 4-6 mm (Fig. 3). Carefully verify that the needle is not intravascular by gentle negative aspiration before inject-



**Fig 3.—Auriculotemporal nerve block.**

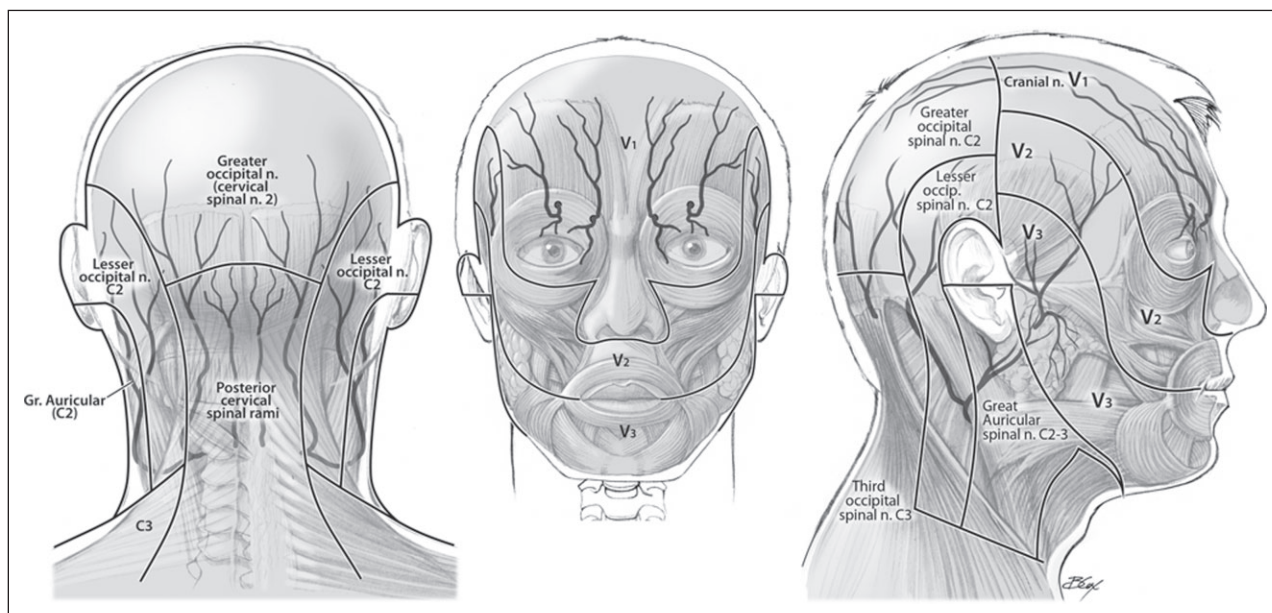
ing. Additional injections may be performed more superiorly, at the temporal fossa, where the nerve gives off multiple branches. Alternatively, insert the needle at the posterior margin of the mandibular ramus, at a level just inferior to the tragus. Inject at a depth of 20 mm at this point.

*Volume of injection:* 0.5-1.0 mL for the single injection at the proximal part of the nerve (more if injecting the superior branches as well, 0.25 mL for each additional injection).

Drugs used are the same as for the STN and SON blocks.

**Outcome.**—Specific outcomes that are commonly reported relate to both the technical success of the PNB, as well as the clinical outcome, including reduction in head pain, attack frequency, disability, use of rescue medications, and analgesic overuse. A technically successful block will result in anesthesia in the blocked nerve territory (Fig. 4). This achievement is a function of appropriate identification of anatomical landmarks and infiltration of an adequate amount of the selected local anesthetic.

Clinical outcomes can be defined based on the clinical circumstance and indication: when treating a patient with an acute migraine attack for rescue purposes, achieving pain freedom would be an appropri-



**Fig 4.—Cranio-cervical dermatomes.**

ate treatment goal, while in treating a CH patient, terminating the headache cycle would be a more reasonable objective. PNBs are also used for transitional therapy in patients with medication overuse, during the weaning period, and as a preventive treatment in patients with chronic daily headache (CDH). Outcome parameters include not only pain relief, but also the ability to return to normal level of activity. The probability of a desirable clinical and functional outcome can be improved with technically successful blocks, as well as with education of the patient regarding appropriate expectations.

Reinjection can be performed as clinically indicated. Typically, this would occur for patients with migraine in at least 2-4 week intervals, as the benefits usually last days to weeks, although the duration of therapeutic effect varies among patients. However, recent evidence suggests that PNBs to suppress a CH attack period may be beneficial and safe with a series of 3 injections, each 48 to 72 hours apart.<sup>7</sup> The indication for treatment will also affect the decision on when to reinject: for the purpose of rescue care of an individual attack, re-treatment is unlikely to be necessary if the patient experiences prompt pain relief. Conversely, for transitional care in an individual who is weaning from pain medication overuse, there may be a need for re-treatment in 2-4 weeks. In patients

using injection therapy for CDH prevention, longer treatment intervals, of 1 month or more, may be sufficient. The particular time interval between injections in these cases should be tailored to the individual patient's response pattern.

The medication used for injection can also be a factor in choice of treatment intervals. Bupivacaine can potentially cause myotoxicity at the site of injection, and some injectors will limit its use accordingly, although its incidence is not well established.<sup>9</sup> Corticosteroid injection may be associated with both local and systemic AEs, such as alopecia, cutaneous atrophy, hyperpigmentation, and Cushing's syndrome, especially with frequent injections at high doses of the drug.<sup>10,11</sup> Therefore, more caution is warranted in these cases, and injections may need to be performed less frequently to minimize systemic or local AEs.

**The Use of Corticosteroids in PNBs.**—Reports have suggested that corticosteroids may be beneficial in certain headache diagnoses including CH, headache related to sexual activity, cervicogenic headaches, episodic migraine with and without aura, hemiplegic migraine with prolonged aura, chronic migraine, hemicrania continua, and post-traumatic headache.<sup>4,7,8,12-18</sup> Corticosteroids may be beneficial in GON blocks in reducing dynamic mechanical allodynia in migraine patients.<sup>12</sup> Triamcinolone, methylprednisolone,

**Table 3.—Corticosteroids Commonly Used in Peripheral Nerve Blocks for the Treatment of Headache Disorders – Approximate Dose Equivalents (to Triamcinolone 1 mg) and Half-Life<sup>44</sup>**

| Corticosteroid     | Equivalent to Triamcinolone 1 mg (mg) | Biologic Half-Life (Hours) | Dose Range Reported Per Individual GON Block (mg) |
|--------------------|---------------------------------------|----------------------------|---|
| Triamcinolone      | 1.0                                   | 18-36 (intermediate)       | 5 mg-40   |
| Methylprednisolone | 1.0                                   | 18-36 (intermediate)       | 20 mg-160   |
| Betamethasone      | 0.15                                  | 36-54 (long)               | 18  |
| Dexamethasone      | 0.19                                  | 36-54 (long)               | 4   |

GON = greater occipital nerve.

dexamethasone, betamethasone (dipropionate long-acting salt and disodium phosphate rapid-acting salt), and cortivazol are the most commonly reported corticosteroids used in the management of patient with headache disorders.<sup>4,7,8,12,14,16,17</sup> Clinically, corticosteroids used in GON blockade for the management of headache disorders are usually used in combination with a local anesthetic. However, treatment of migraine with GON blocks using only corticosteroids has been reported.<sup>19</sup>

Table 3 lists the commonly used corticosteroids as well as their half-life and equivalence to triamcinolone. Although the dose range of corticosteroids in GON blocks varies, with dosages as high as 160 mg of methylprednisolone reported, triamcinolone 40-60 mg, or an equivalent dose of a different steroid, in combination with a local anesthetic, may be adequate for headache disorders.<sup>12,14,16,19-21</sup>

Study results for the use of corticosteroids in GON blocks have been mixed. This may be due to the different doses and steroid types used in the different studies, as well as the variability in headache disorders evaluated. In a controlled study of patients with transformed migraine, GON block using the combination of triamcinolone and local anesthetics was not significantly more effective than injecting local anesthetic alone.<sup>20</sup> In a randomized controlled study of CH patients, however, the suboccipital injection of betamethasone and lidocaine was significantly more effective than saline and lidocaine in inducing headache remission.<sup>8</sup> These findings were supported by data from a recent randomized controlled study, showing that the suboccipital injection of cortivazol

was more effective than placebo in decreasing CH attack frequency.<sup>7</sup> More placebo-controlled studies are needed to further assess the efficacy of steroids in the treatment of various headache disorders.

Practically, patients should be informed that the onset of pain relief from steroids is probably slower than that of a local anesthetic, and thus their analgesic effect may not occur within the first 20 minutes of injections. Due to potential local and systemic AEs, the cautious use of corticosteroids is warranted in all patients, and particularly in those with diabetes or glaucoma.<sup>22</sup> Corticosteroids should be avoided when performing PNBs in the trigeminal branches, due to potential local AEs, including cutaneous atrophy.<sup>10</sup>

## SUMMARY

The said recommendations represent the current recommendations among the AHS-IPS members on this topic. It should be noted that there is a paucity of evidence from controlled studies for the use of PNBs in the treatment of primary and secondary headache disorders, with the exception of GON blockade for CH. Further research on this topic is strongly encouraged, and may result in revision of the said recommendations, aiming at further improving the outcome and safety of this treatment modality for headache.

## REFERENCES

1. Ashkenazi A, Levin M, Dodick D. Peripheral procedures: Nerve blocks, peripheral neurostimulation, and Botulinum neurotoxin injections. In: Silberstein S, Lipton R, Dodick D, eds. *Wolff's Headache and*



- Other Head Pain*. New York: Oxford University Press; 2007:767-792.
2. Ashkenazi A, Blumenfeld A, Napchan U, et al. Peripheral nerve blocks and trigger point injections in headache management – A systematic review and suggestions for future research. *Headache*. 2010;50:943-952.
  3. Blumenfeld A, Ashkenazi A, Grosberg B, et al. Patterns of use of peripheral nerve blocks and trigger point injections among headache practitioners in the USA: Results of the American Headache Society Interventional Procedure Survey (AHS-IPS). *Headache*. 2010;50:937-942.
  4. Afridi SK, Shields KG, Bhola R, Goadsby PJ. Greater occipital nerve injection in primary headache syndromes – Prolonged effects from a single injection. *Pain*. 2006;122:126-129.
  5. Bartsch T, Goadsby PJ. Stimulation of the greater occipital nerve induces increased central excitability of dural afferent input. *Brain*. 2002;125:1496-1509.
  6. Rosenberg PH, Veering BT, Urmey WF. Maximum recommended doses of local anesthetics: A multifactorial concept. *Reg Anesth Pain Med*. 2004;29:564-575. discussion 524.
  7. Leroux E, Valade D, Taifas I, et al. Suboccipital steroid injections for transitional treatment of patients with more than two cluster headache attacks per day: A randomised, double-blind, placebo-controlled trial. *Lancet Neurol*. 2011;10:891-897.
  8. Ambrosini A, Vandenheede M, Rossi P, et al. Suboccipital injection with a mixture of rapid- and long-acting steroids in cluster headache: A double-blind placebo-controlled study. *Pain*. 2005;118:92-96.
  9. Zink W, Graf BM. Local anesthetic myotoxicity. *Reg Anesth Pain Med*. 2004;29:333-340.
  10. Shields KG, Levy MJ, Goadsby PJ. Alopecia and cutaneous atrophy after greater occipital nerve infiltration with corticosteroid. *Neurology*. 2004;63:2193-2194.
  11. Lavin PJ, Workman R. Cushing syndrome induced by serial occipital nerve blocks containing corticosteroids. *Headache*. 2001;41:902-904.
  12. Ashkenazi A, Young WB. The effects of greater occipital nerve block and trigger point injection on brush allodynia and pain in migraine. *Headache*. 2005;45:350-354.
  13. Busch V, Jakob W, Juergens T, Schulte-Mattler W, Kaube H, May A. Occipital nerve blockade in chronic cluster headache patients and functional connectivity between trigeminal and occipital nerves. *Cephalalgia*. 2007;27:1206-1214.
  14. Peres MF, Stiles MA, Siow HC, Rozen TD, Young WB, Silberstein SD. Greater occipital nerve blockade for cluster headache. *Cephalalgia*. 2002;22:520-522.
  15. Bigo A, Delrieu F, Bousser MG. [Treatment of vascular pain of the face by methylprednisolone injection into the area of the greater occipital nerve: 16 cases]. *Rev Neurol (Paris)*. 1989;145:160-162.
  16. Rozen T. Cessation of hemiplegic migraine auras with greater occipital nerve blockade. *Headache*. 2007;47:917-919.
  17. Selekler M, Kutlu A, Dundar G. Orgasmic headache responsive to greater occipital nerve blockade. *Headache*. 2009;49:130-131.
  18. Guerrero AL, Herrero-Velazquez S, Penas ML, et al. Peripheral nerve blocks: A therapeutic alternative for hemicrania continua. *Cephalalgia*. 2012;32:505-508.
  19. Tobin J, Flitman S. Treatment of migraine with occipital nerve blocks using only corticosteroids. *Headache*. 2011;51:155-159.
  20. Ashkenazi A, Matro R, Shaw JW, Abbas MA, Silberstein SD. Greater occipital nerve block using local anaesthetics alone or with triamcinolone for transformed migraine: A randomised comparative study. *J Neurol Neurosurg Psychiatry*. 2008;79:415-417.
  21. Anthony M. Headache and the greater occipital nerve. *Clin Neurol Neurosurg*. 1992;94:297-301.
  22. Tripathi RC, Parapuram SK, Tripathi BJ, Zhong Y, Chalam KV. Corticosteroids and glaucoma risk. *Drugs Aging*. 1999;15:439-450.
  23. Gawel MJ, Rothbart PJ. Occipital nerve block in the management of headache and cervical pain. *Cephalalgia*. 1992;12:9-13.
  24. Caputi CA, Firetto V. Therapeutic blockade of greater occipital and supraorbital nerves in migraine patients. *Headache*. 1997;37:174-179.
  25. Bovim G, Sand T. Cervicogenic headache, migraine without aura and tension-type headache. Diagnostic blockade of greater occipital and supra-orbital nerves. *Pain*. 1992;51:43-48.
  26. Dimitriou V, Iatrou C, Malefaki A, Pratsas C, Simopoulos C, Voyagis GS. Blockade of branches of the ophthalmic nerve in the management of acute attack of migraine. *Middle East J Anesthesiol*. 2002;16:499-504.

27. Leinisch-Dahlke E, Jürgens T, Bogdahn U, Jakob W, May A. Greater occipital nerve block is ineffective in chronic tension type headache. *Cephalalgia*. 2005;25:704-708.
28. Saadah HA, Taylor FB. Sustained headache syndrome associated with tender occipital nerve zones. *Headache*. 1987;27:201-205.
29. Robbins MS, Grosberg BM, Napchan U, Crystal SC, Lipton RB. Clinical and prognostic subforms of new daily-persistent headache. *Neurology*. 2010;74:1358-1364.
30. Anthony M. Cervicogenic headache: Prevalence and response to local steroid therapy. *Clin Exp Rheumatol*. 2000;18:S59-S64.
31. Naja ZM, El-Rajab M, Al-Tannir MA, Ziade FM, Tawfik OM. Repetitive occipital nerve blockade for cervicogenic headache: Expanded case report of 47 adults. *Pain Pract*. 2006;6:278-284.
32. Vincent MB, Luna RA, Scanduzzi D, Novis SA. Greater occipital nerve blockade in cervicogenic headache. *Arq Neuropsiquiatr*. 1998;56:720-725.
33. Inan N, Ceyhan A, Inan L, Kavaklioglu O, Alptekin A, Unal N. C2/C3 nerve blocks and greater occipital nerve block in cervicogenic headache treatment. *Funct Neurol*. 2001;16:239-243.
34. Naja ZM, El-Rajab M, Al-Tannir MA, Ziade FM, Tawfik OM. Occipital nerve blockade for cervicogenic headache: A double-blind randomized controlled clinical trial. *Pain Pract*. 2006;6:89-95.
35. Hecht JS. Occipital nerve blocks in postconcussive headaches: A retrospective review and report of ten patients. *J Head Trauma Rehabil*. 2004;19:58-71.
36. Naja Z, Al-Tannir M, El-Rajab M, Ziade F, Baraka A. Nerve stimulator-guided occipital nerve blockade for postdural puncture headache. *Pain Pract*. 2009;9:51-58.
37. Sjaastad O, Stolt-Nielsen A, Pareja JA, Fredriksen TA, Vincent M. Supraorbital neuralgia. On the clinical manifestations and a possible therapeutic approach. *Headache*. 1999;39:204-212.
38. Pareja JA, Caminero AB. Supraorbital neuralgia. *Curr Pain Headache Rep*. 2006;10:302-305.
39. Mulero P, Guerrero AL, Pedraza M, et al. Non-traumatic supraorbital neuralgia: A clinical study of 13 cases. *Cephalalgia*. 2012;32:1150-1153.
40. Speciali JG, Gonçalves DA. Auriculotemporal neuralgia. *Curr Pain Headache Rep*. 2005;9:277-280.
41. Sahai-Srivastava S, Subhani D. Adverse effect profile of lidocaine injections for occipital nerve block in occipital neuralgia. *J Headache Pain*. 2010;11:519-523.
42. Okuda Y, Matsumoto T, Shinohara M, Kitajima T, Kim P. Sudden unconsciousness during a lesser occipital nerve block in a patient with the occipital bone defect. *Eur J Anaesthesiol*. 2001;18:829-832.
43. Sprenger T, Seifert CL. Coma after greater occipital nerve blockade in a patient with previous posterior fossa surgery. *Headache*. 2012. Epub ahead of print 18 Dec 2012.
44. McAuley D. Corticosteroids conversion calculator. <http://www.globalrph.com/corticocalc.htm>. Accessed January 29, 2012.